

## Neck ultrasound and Tg levels but not a diagnostic $^{131}\text{I}$ scans are useful tools during follow-up of patients with persistent $^{131}\text{I}$ neck uptake on diagnostic whole-body $^{131}\text{I}$ scans

Kim EY, Kim WG, Kim WB, Kim TY, Ryu JS, Gong G, Yoon JH, Hong SJ, Lee JH, Baek JH, Shong YK. Clinical outcomes of persistent radioiodine uptake in the neck shown by diagnostic whole body scan in patients with differentiated thyroid carcinoma after initial surgery and remnant ablation. *Clin Endocrinol (Oxf)* 2010;73:257-63.

### SUMMARY

#### BACKGROUND

Patients with differentiated thyroid cancer (DTC) usually are initially treated with total or near-total thyroidectomy and radioactive iodine ( $^{131}\text{I}$ ) for thyroid remnant ablation. This is a retrospective study that is focused on the subset of patients who have residual uptake of  $^{131}\text{I}$  following their preliminary treatment. The aim of the study is to assess the efficacy of a second remnant ablation in this situation.

#### PATIENTS AND METHODS

##### Patients

The study subjects were 874 consecutive patients with DTC who were treated from January 2000 through January 2004 with total thyroidectomy followed by immediate  $^{131}\text{I}$  remnant ablation, according to the protocol established by the Endocrinology Department of the Asan Medical Center in Seoul, Korea. Excluded from the study were patients with distant metastases or with  $^{131}\text{I}$  uptake (RAIU) outside the thyroid bed on the initial posttherapy whole-body scan (RxWBS), and patients with serum thyroglobulin (Tg) antibody (TgAb) concentrations  $>100$  U/ml. One year after remnant ablation, a diagnostic whole-body  $^{131}\text{I}$  scan (RxWBS) was performed in 782 of the 874 (90%) patients who had serum TSH concentrations  $>30$  mIU/L after thyroid hormone withdrawal (THW). Ablation activities were 30, 80, and 150 mCi (1.11, 2.96, and 5.55 GBq, respectively), depending on the tumor size and the presence of extrathyroidal tumor extension and lymph-node metastases. The 572 patients who received high  $^{131}\text{I}$  activities (150 mCi) were included in the retrospective study. Excluded were patients who received 30 or 80 mCi.

##### Initial Treatment and Follow-up with Diagnostic Whole-Body Scan

Patients had THW during the 5 to 6 weeks after initial surgery; all received 150 mCi of  $^{131}\text{I}$ , followed by RxWBS 2 to 7 days after the administration of  $^{131}\text{I}$ . Suppressive treatment with thyroid hormone was started 2 days after the administration of  $^{131}\text{I}$  to decrease serum thyrotropin (TSH) levels in patients without clinical thyrotoxicosis. After 4 weeks of THW with a TSH of  $>30$  mIU/L, a diagnostic whole-body scan (DxWBS) was performed with 4 mCi of  $^{131}\text{I}$ ; this was usually 12 months after remnant ablation and when serum Tg and TgAb levels were measured. A successful remnant ablation was defined as the absence of abnormal  $^{131}\text{I}$  uptake in the DxWBS.

##### Definitions of Recurrence and Persistent Disease

Tumor recurrence was defined as the reappearance of tumor after complete remnant ablation, which was confirmed by cytologic or histopathological examination or persistent extracervical uptake on RxWBS after the administration of 150 mCi of  $^{131}\text{I}$ .

##### Measurements of Tg, TgAb, and TSH

These laboratory studies were performed at the time of DxWBS or during THW for the administration of  $^{131}\text{I}$  for remnant ablation. The stimulated Tg (sTg) at the initial DxWBS measured 1 year after initial treatment was sTg1; sTg2 was the sTg measured 2 years after the initial therapy.

##### Whole-Body Scanning and Other Imaging Studies

Patients with distant metastases or persistent uptake in the neck found 1 year after remnant ablation on a THW-stimulated 4 mCi  $^{131}\text{I}$  DxWBS had DxWBS every year thereafter.

Patients with high-risk tumors had periodic DxWBS with Tg measurement after THW. RxWBS was performed 2 to 7 days after the administration of 150 mCi of  $^{131}\text{I}$ . All patients were advised to restrict dietary iodine intake for at least 15 days before  $^{131}\text{I}$  therapy. Patients with low-risk tumors had yearly neck ultrasonography and Tg measurements during THW.

##### Neck Ultrasonography

Ultrasound examinations of the neck were performed by two experienced radiologists. Using high-resolution phase-array linear transducers, the thyroid bed was scanned for the presence of hypoechoic abnormalities with marginal spiculation, microcalcification, or nodules whose appearance was taller than it was wide, suggesting locoregional recurrence. The lateral neck was evaluated for lymph-node metastases, which were determined by calcification, cystic changes, and cortical hyperechogenicity, with or without a round configuration; these were further studied by ultrasound-guided fine-needle aspiration biopsy.

##### Subsequent Management and Follow-up of Patients with Persistent RAIU on the First DxWBS

Patients with undetectable sTg and negative neck ultrasonography were observed without further therapy. Patients with limited intrathyroidal disease without regional lymph-node metastases at surgery (very-low-risk group) did not undergo a second ablation, if neck ultrasonography was negative, even if their serum sTg concentrations were mildly elevated (to 2.2  $\mu\text{g}/\text{L}$  in one patient and 8.5  $\mu\text{g}/\text{L}$  in another).

**RESULTS**

**Patient Characteristics (Figure 1)**

The study subjects comprise 572 patients, 70 men (12%) and 502 women (88%), mean (±SD) age 46.7±12.4 (range, 9.7 to 79.4). Of this group, 550 (96%) patients had conventional papillary thyroid cancer (PTC), 14 (2%) had follicular variant PTC, and 8 (1.4%), and 14 (2.4%) had Hürthle-cell carcinomas. The mean tumor size was 2.1±1.3 cm, and the tumors that were multifocal (54.5%), had extrathyroidal extensions (79.4%), and lymph-node metastases (64.9%), although none had evidence of distant metastases at the time of entry into the study. Of these 572 patients, 258 (45%) had tumor–node–metastasis (TNM) stage I, 8 (1.4%) had stage II, 262 had stage III, and 44 had stage IV-A.

**Clinicopathological Factors Related to Persistent Uptake in the Neck at DxWBS**

A total of 25 of the 572 patients (4.4%) had persistent RAIU in the neck on DxWBS. Among this group of 25, there were no differences in age (P = 0.19), sex (P = 0.53), tumor size (P = 0.84), multifocality (P = 0.31), extrathyroidal extension (P = 0.32), cervical-lymph-node metastases (P = 0.1) comparing the positive and negative remnant-uptake groups.

**Association of Persistent Disease with Persistent DxWBS Uptake in the Neck (Figure 2)**

Of the 25 patients in the remnant-positive group, 5 (20%) had recurrent or persistent disease after a median follow-up of 65.7 months (range, 7.5 to 118.5), as compared with 67 of the 547 patients (12%) in the remnant-negative group. There was no significance in disease-free survival in the two groups (P = 0.169).

Univariate analysis found that the clinicopathological factors associated with recurrent or persistent disease were sex (hazard ratio [HR], 2.60; P = 0.002), tumor multifocality (HR, 2.12; P = 0.002), and cervical lymph-node metastases (N1a; HR, 2.44; P < 0.001; and N1b; HR, 4.31; P < 0.001), without persistent RAIU in the neck on DxWBS (HR, 1.87; P = 0.216) (Figure 2).

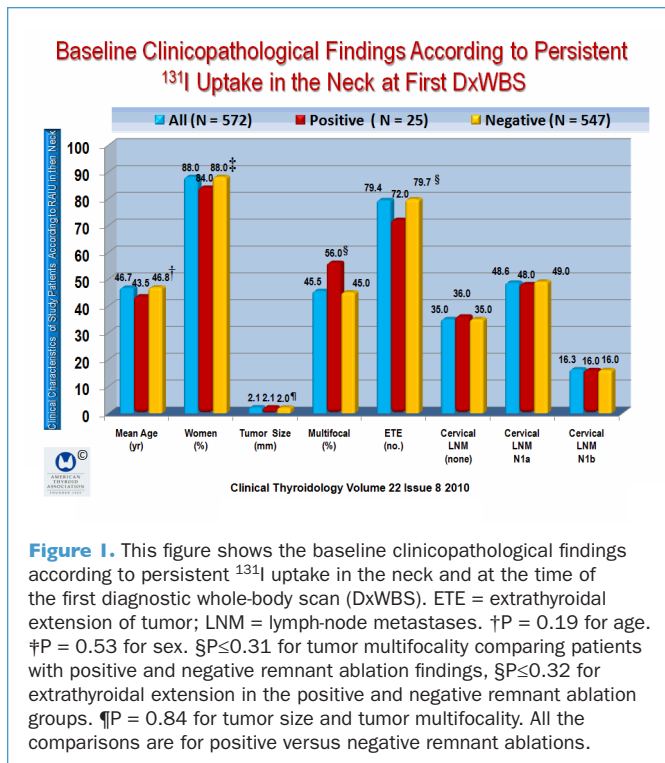
Multivariate analysis found that sex (HR, 2.63), tumor multifocality (HR, 2.01; P = 0.004), and cervical-lymph-node metastases N1a (HR, 2.29; P < 0.001) and N1b (HR, 3.84; P < 0.001) each had an independent association with persistent disease.

At the time of the first DxWBS, all of the patients who had reoperation had cervical-lymph-node metastases on neck ultrasonography, and sTg concentrations >2 µg/L; whereas 6 patients in the second ablation group had detectable serum sTg, and all of the patients in the observational group had negative ultrasonography and only 2 had undetectable serum sTg levels.

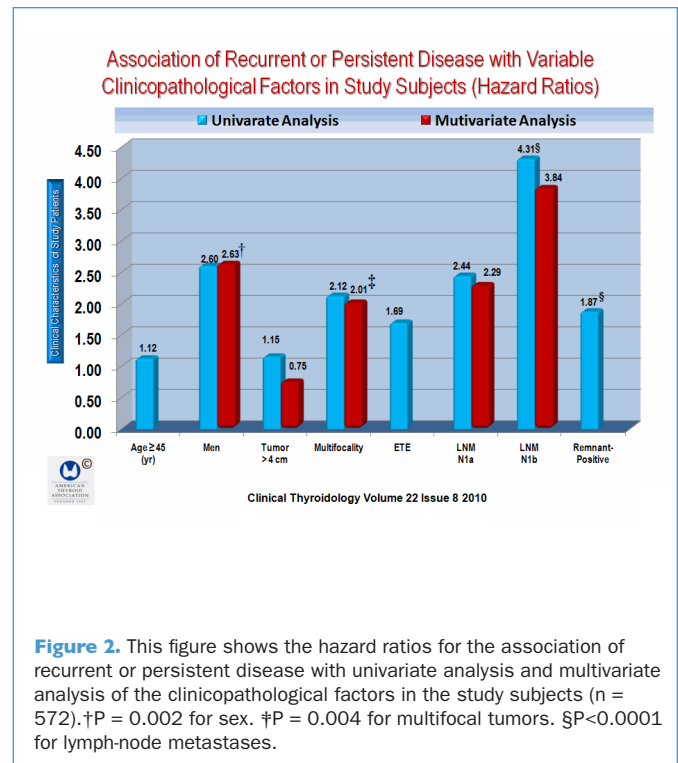
At the time of Tg measurements, TgAb was not detected in any patients, and TSH levels were >30 mIU/L. In the second ablation group, sTg levels decreased and became undetectable during the follow-up in all but one patient, whereas the observation group had sTg concentrations that spontaneously decreased during follow-up and the TSH had undetectable sTg at the time of the final evaluation.

**CONCLUSION**

Neck ultrasound and Tg levels but not diagnostic <sup>131</sup>I scans are useful tools during the follow-up of patients with persistent <sup>131</sup>I neck uptake on diagnostic whole-body <sup>131</sup>I scans.



**Figure 1.** This figure shows the baseline clinicopathological findings according to persistent <sup>131</sup>I uptake in the neck and at the time of the first diagnostic whole-body scan (DxWBS). ETE = extrathyroidal extension of tumor; LNM = lymph-node metastases. †P = 0.19 for age. ‡P = 0.53 for sex. §P ≤ 0.31 for tumor multifocality comparing patients with positive and negative remnant ablation findings, ¶P ≤ 0.32 for extrathyroidal extension in the positive and negative remnant ablation groups. ¶P = 0.84 for tumor size and tumor multifocality. All the comparisons are for positive versus negative remnant ablations.



**Figure 2.** This figure shows the hazard ratios for the association of recurrent or persistent disease with univariate analysis and multivariate analysis of the clinicopathological factors in the study subjects (n = 572). †P = 0.002 for sex. ‡P = 0.004 for multifocal tumors. §P < 0.0001 for lymph-node metastases.

**COMMENTARY**

Although the 25 patients with persistent <sup>131</sup>I uptake in the neck were evaluated for persistent disease, neck ultrasonography and other imaging methods showed that only five patients had tumor in cervical-lymph-node compartments, all of which appeared to be cured by surgery, confirmed by negative serum sTg levels and negative neck ultrasonography during follow-up after the second surgery. Seven patients had a second <sup>131</sup>I ablation and all have remained free of disease, with absence of neck RAIU 1 year after the second ablation; 2 other patients with persistent neck uptake even after a second ablation had negative ultrasound findings. All 13 patients in the observation group were disease-free during the observation period, during which 10 had second DxWBS 12 months later. In 5 of these patients, neck uptake vanished spontaneously, although a third DxWBS was not performed.

Perhaps one of the more important observations was a 50% spontaneous remission in patients with no ultrasound abnormalities and undetectable sTg or who were at very low risk. The authors suggest that as no patient in the observation group had recurrence disease, a second <sup>131</sup>I ablation may not be necessary in low-risk patients with persistent neck uptake, negative neck ultrasonography, despite the presence of mildly elevated serum Tg levels.

The authors concluded that success of remnant ablation was not an independent risk factor predicting recurrence in low-risk patients with DTC.

This study is not dissimilar to a study by Al-Saif et al. (1) of 95 consecutive patients with recurrent or persistent PTC in the neck, all of whom had previous thyroidectomy with or without cervical-lymph-node dissection and <sup>131</sup>I therapy. A total of 25 patients with TgAb were excluded from the study. The main outcome was complete remission, defined as undetectable TSH-

stimulated serum Tg with no imaging evidence of disease. A total of 107 lymphadenectomies were performed in 70 patients and remission was initially achieved in 12 (17%). Of the 58 patients with detectable postoperative Tg, 28 had a second reoperation, and remission was achieved in 5 (18%), 7 had a third reoperation, and none achieved remission. No patient achieving a remission had a recurrence after a mean follow-up of 60 months. In addition, two more patients achieved remission during a long-term follow-up without further intervention.

In total, 19 patients (27%) achieved remission and 32 (46%) achieved a TSH-stimulated Tg <2.0 ng/ml. Patients who did not achieve a remission had a significant reduction in Tg after the first (P<0.001) and second (P = 0.008) operations. No patient had detectable distant metastases or died from PTC. The main finding was that surgical resection of persistent PTC in cervical lymph nodes achieves remission, which was 27% when stringently defined, sometimes requiring several surgeries, and no clinical recurrences occurred during follow-up. In patients who do not achieve remission, Tg levels were significantly reduced. The authors offered the caveat that long-term durability and impact of this intervention will require further investigation.

The ATA guidelines recommend that <sup>131</sup>I when RxWBS is positive for uptake only in the thyroid bed, follow-up should be 6 to 12 months. The algorithm suggests that a positive DxWBS should be considered for <sup>131</sup>I therapy (2).

There is a general consensus that diagnostic whole-body <sup>131</sup>I scans are not routinely recommended for follow-up and TSH-stimulated serum Tg and neck ultrasonography are more likely to identify persistent or recurrent disease. Also, a serum Tg measurement that is rising is much more likely to identify persistent disease, and conversely, a declining serum Tg is a harbinger of successful therapy (3-5).

— Ernest L. Mazzaferri, MD, MACP

**References**

1. Al-Saif O, Farrar WB, Bloomston M, et al. Long-term efficacy of lymph node reoperation for persistent papillary thyroid cancer. *J Clin Endocrinol Metab* 2010;95:2187-94.
2. Cooper DS, Doherty GM, Haugen BR, et al. Revised American Thyroid Association management guidelines for patients with thyroid nodules and differentiated thyroid cancer. *Thyroid* 2009;19:1167-214.
3. Kloos RT, Mazzaferri EL. A single recombinant human thyrotropin-stimulated serum thyroglobulin measurement predicts differentiated

- thyroid carcinoma metastases three to five years later. *J Clin Endocrinol Metab* 2005;90:5047-57.
4. Mazzaferri EL, Kloos RT. Using recombinant human TSH in the management of well-differentiated thyroid cancer: current strategies and future directions. *Thyroid* 2000;10:767-78.
5. Baudin E, Do Cao C, Cailleux AF, et al. Positive predictive value of serum thyroglobulin levels, measured during the first year of follow-up after thyroid hormone withdrawal, in thyroid cancer patients. *J Clin Endocrinol Metab* 2003;88:1107-11.