

# The first administration of radioiodine following total thyroidectomy for differentiated thyroid cancer ablates both the thyroid remnant and residual tumor

Tuttle RM, Lopez N, Leboeuf R, Minkowitz SM, Grewal R, Brokhin M, Omry G, Larson S. Radioactive iodine administered for thyroid remnant ablation following recombinant human thyroid stimulating hormone preparation also has an important adjuvant therapy function. *Thyroid* 2010;20:257-63.

## SUMMARY

### BACKGROUND

Previously undetected radioiodine-avid metastases are often found in the process of treating patients with radioiodine (<sup>131</sup>I) for postsurgical thyroid remnant ablation (RRA). It is not entirely clear whether this happens only when using thyroid hormone withdrawal for RRA (THW-RRA) or also occurs with recombinant human thyrotropin (rhTSH-RRA). Moreover, there is uncertainty about whether RRA effectively ablates these previously undetected metastases. The aim of this study was to determine whether rhTSH-RRA has an adjunctive therapeutic effect on metastases found during rhTSH-RRA.

### METHODS

The study subjects were 394 patients treated for well-differentiated PTC or follicular cancer at the Memorial Sloan-Kettering Cancer Center from 1997 through 2005. Excluded from the study were patients with known distant metastases or antithyroglobulin antibodies. The decision to prepare patients for RRA with rhTSH or THW was made at the discretion of the attending physicians. The amount of <sup>131</sup>I used for RRA in each patient was based on the opinion of a multidisciplinary group of the Thyroid Cancer Board. All had total or near-total thyroidectomy with no known residual tumor or metastatic disease, which was followed by RRA performed without dosimetry. Of this group, 84 (21%) had <sup>131</sup>I uptake outside the thyroid bed.

Cross-sectional imaging studies were not routinely performed at the time of RRA in patients known to have <sup>131</sup>I-avid cervical uptake. However, all patients who had <sup>131</sup>I-avid uptake in the lungs had computed tomography (CT) of the chest. The authors were thus able to identify structural correlates in patients with lung <sup>131</sup>I uptake on the RRA scans, but not in patients with <sup>131</sup>I uptake outside the bed but confined to the neck.

Follow-up was done at 6- to 12-month intervals in most patients, depending on the patient's risk for persistent disease. Follow-up at 12 to 18 months after RRA included an rhTSH-stimulated whole-body diagnostic <sup>131</sup>I scan (DxWBS), which was done in most patients, at the discretion of the attending physician, with or without CT studies. Patients were classified as having no evidence of disease (NED) if they had a negative DxWBS or a serum thyroglobulin (Tg) <2 ng/ml, whereas patients were classified as having persistent disease if the DxWBS showed <sup>131</sup>I-avid disease with or without a stimulated serum Tg >2 ng/ml.

## RESULTS

Of the 84 patients who had <sup>131</sup>I-avid uptake in metastatic lesions outside the thyroid bed, 63 had uptake on the initial diagnostic <sup>131</sup>I scan (75%) and 21 (25%) had <sup>131</sup>I-avid tumors identified in

the posttreatment scan (RxWBS). Of the 84 patients 64 (76%) were prepared for rhTSH-RRA and 20 (24%) were prepared with THW-RRA. In 68 patients (81%) the DxWBS was performed 12 to 18 months after RRA (Figure 1).

### Patient and Tumor Characteristics (Figures 1, 2, and 3)

Age, sex, tumor histology, clinical tumor–node–metastasis (TNM) classification, and disease stage were not statistically different in the rhTSH-RRA and THW-RRA groups (Figure 1). Although all patients were considered to be free of distant metastases prior to ablation, 8 of the 84 patients with <sup>131</sup>I-avid metastatic tumors had distant metastases (4 each with rhTSH-RRA or THW-RRA), five of whom had lung metastases alone (Figure 2). Their TNM tumor stage was thus changed from M0 to M1. The median <sup>131</sup>I activity administered was 144 mCi in the rhTSH-RRA group and 108 mCi in the THW-RRA group (P = 0.307) (Figure 2).

The <sup>131</sup>I-avid tumors were initially identified on the <sup>131</sup>I DxWBS in most patients either with rhTSH-RRA (75%) or THW-RRA (90%) (P = 0.2). In both groups, <sup>131</sup>I-avid tumors were mainly identified as locoregional <sup>131</sup>I-avid metastases alone that were found in 60 of 64 patients prepared with rhTSH-RRA (94%) and in 16 of 20 prepared with THW-RRA (80%) (Figure 3). The rest of the patients either had lung metastases alone, 3 in the rhTSH-RRA group (5%) and 2 (10%) in the THW-RRA group, or with locoregional metastases with lung metastases, 6% in the rhTSH-RRA group and 20% in the THW-RRA group) (Figure 3).

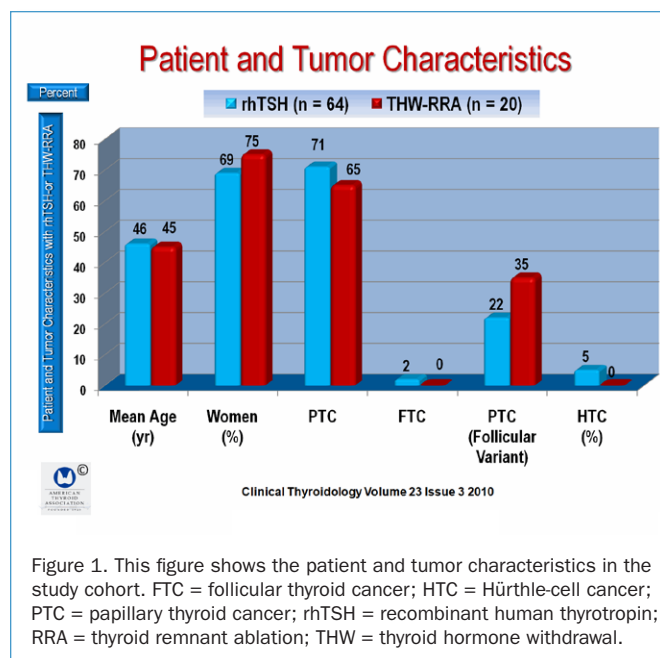


Figure 1. This figure shows the patient and tumor characteristics in the study cohort. FTC = follicular thyroid cancer; HTC = Hürthle-cell cancer; PTC = papillary thyroid cancer; rhTSH = recombinant human thyrotropin; RRA = thyroid remnant ablation; THW = thyroid hormone withdrawal.

**Clinical Outcomes (Figure 4 and 5)**

A median of 2.7 years after performing RRA, a total of 45 of 64 patients (70%) in the rhTSH-RRA group, and 11 of 20 in the THW-RRA group (55%) were classified as having NED, together comprising 56 of 84 patients with NED (67%). The others were classified as having NED. (Figure 4)

**Persistent Disease**

Persistent disease was identified in 19 of 64 patients in the rhTSH-RRA group (30%) and in 9 of 20 patients (45%) in the THW-RRA group (Figure 4), comprising 28 of 84 patients (33%) with persistent disease (Figure 4)

Cross-sectional imaging obtained during follow-up identified persistent locoregional tumors in 5 of 19 patients in the rhTSH-RRA group (26%) and in 4 of 9 in the THW-RRA group (44%), with persistently abnormal serum Tg levels during followup. One patient in the rhTSH-RRA group had non-<sup>131</sup>I-avid lung nodules suspicious for metastases.

Undetectable serum Tg <0.6 ng/ml was achieved in 28 of 64 patients in the rhTSH-RRA group (44%) and 6 of 20 (30%) of the THW-RRA group. However, when NED was defined as an undetectable TSH-stimulated serum Tg value, 25 of the 64 patients (39%) in the rhTSH-RRA group and 5 of the 20 patients

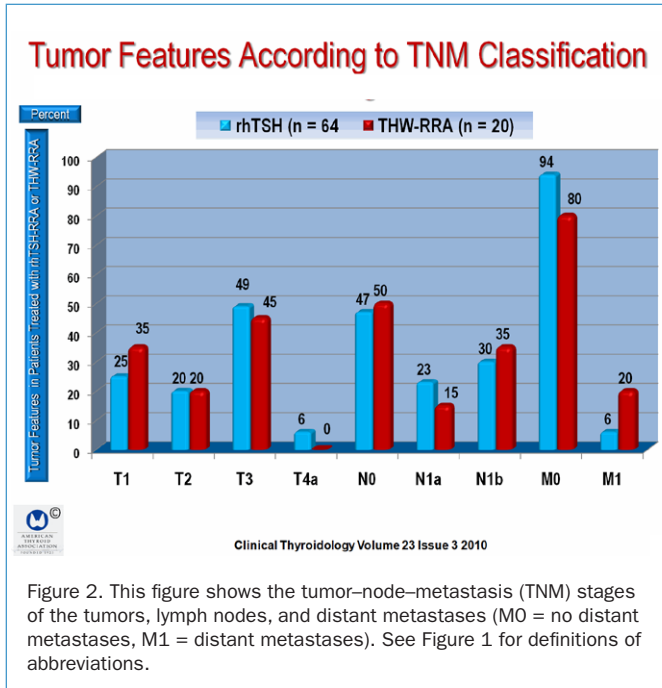


Figure 2. This figure shows the tumor–node–metastasis (TNM) stages of the tumors, lymph nodes, and distant metastases (M0 = no distant metastases, M1 = distant metastases). See Figure 1 for definitions of abbreviations.

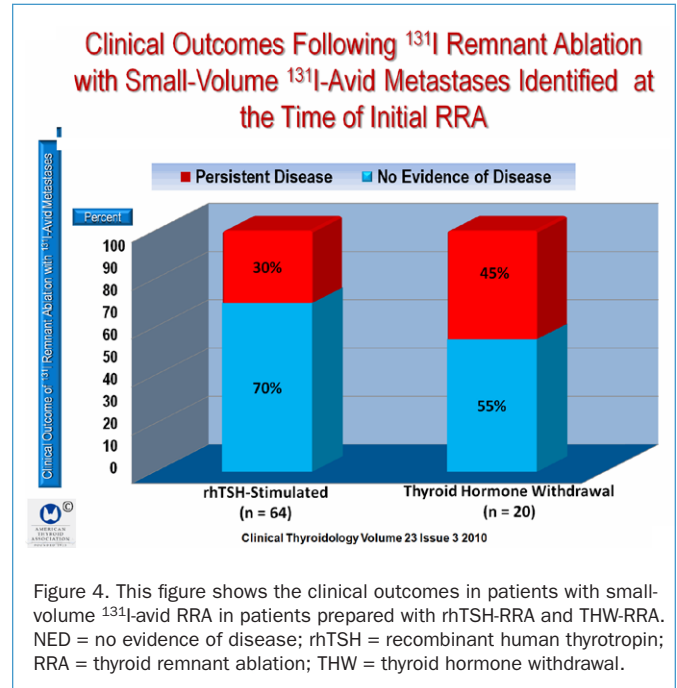


Figure 4. This figure shows the clinical outcomes in patients with small-volume <sup>131</sup>I-avid RRA in patients prepared with rhTSH-RRA and THW-RRA. NED = no evidence of disease; rhTSH = recombinant human thyrotropin; RRA = thyroid remnant ablation; THW = thyroid hormone withdrawal.

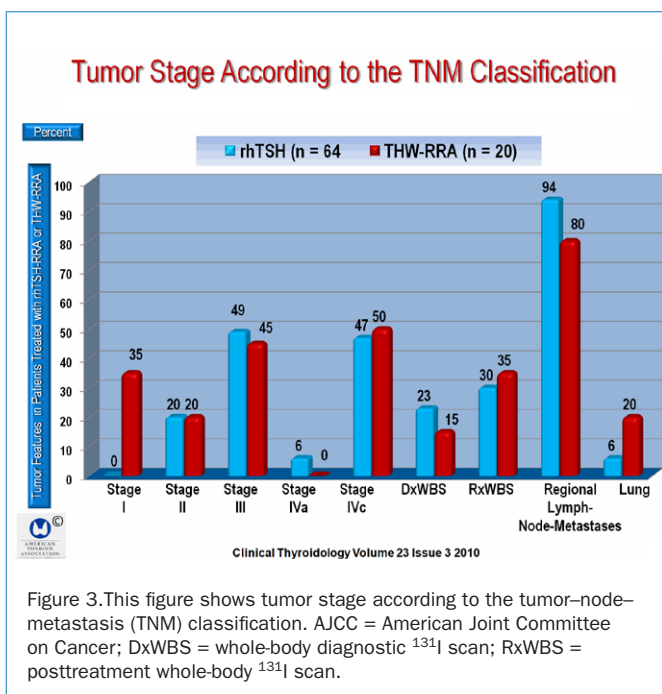


Figure 3. This figure shows tumor stage according to the tumor–node–metastasis (TNM) classification. AJCC = American Joint Committee on Cancer; DxWBS = whole-body diagnostic <sup>131</sup>I scan; RxWBS = posttreatment whole-body <sup>131</sup>I scan.

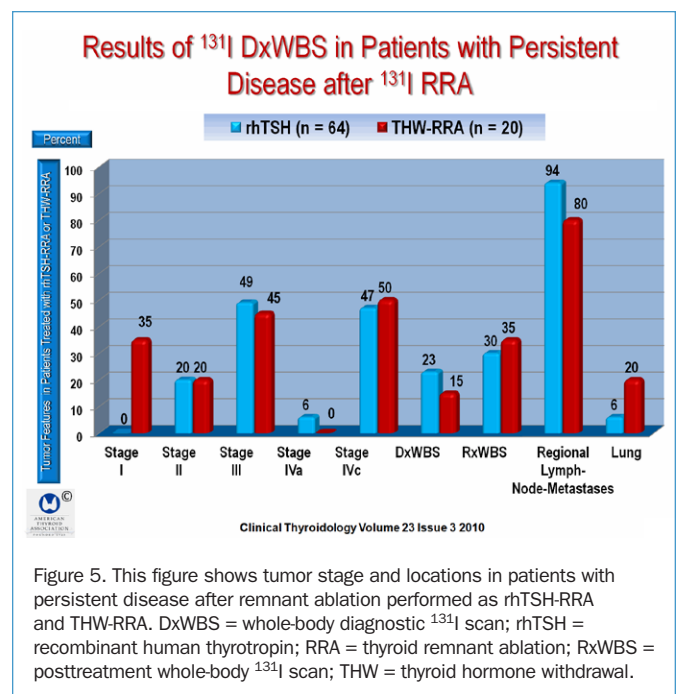


Figure 5. This figure shows tumor stage and locations in patients with persistent disease after remnant ablation performed as rhTSH-RRA and THW-RRA. DxWBS = whole-body diagnostic <sup>131</sup>I scan; rhTSH = recombinant human thyrotropin; RRA = thyroid remnant ablation; RxWBS = posttreatment whole-body <sup>131</sup>I scan; THW = thyroid hormone withdrawal.

(25%) in the THW-RRA group were classified as NED at 12 to 18 months after RRA (P = 0.19).

Among the patients with <sup>131</sup>I-avid tumors identified on the initial DxWBS prior to RRA, 48 of 64 (75%) in the rhTSH-RRA group and 18 of 20 (90%) in the THW-RRA group were found to have persistent disease in the same location on follow-up DXWBS, which identified persistent tumor in the same location in 9 of 48 (19%) of the rhTSH-RRA group and 0 of 18 in the THW-RRA group (P = 0.01).

New areas of <sup>131</sup>I-avid tumor were detected on the follow-up rhTSH-stimulated DxWBS in 1 of 48 patients (2%) in the rhTSH-RRA group and in 2 of 18 (11%) in the THW-RRA group. In this group, there was 1 patient with new uptake in the neck and 1 with new uptake in the lungs (P = 0.17). (Figure 5)

Still, new sites of <sup>131</sup>I-avid tumor were detected during the follow-up rhTSH-stimulated DxWBS in 1 of 48 (2%) patients in the rhTSH-RRA cohort (new uptake in the neck) and in 2 of 18 (11%) in the THW-RRA group (1 patient with new uptake in the neck and 1 with new uptake in the lungs) (P = 0.17).

**Results of the Followup <sup>131</sup>I DXWBS and TSH-stimulated Tg in Patients Classified as having persistent disease after RRA.(Figure 6)**

Among the rhTSH-RRA group, structurally identifiable tumor was associated with a TSH-stimulated Tg >2 ng/ml in all five cases and positive DxWBS in one case. Among the THW-RRA group, three of four patients with structurally identifiable tumor

had a stimulated Tg >2 ng/ml and two had a positive DxWBS. Based on the follow-up DxWBS in patients with persistent tumor, the site of persistent <sup>131</sup>I uptake correlated with the site of <sup>131</sup>I uptake on the preablation DxWBS. The site of persistent <sup>131</sup>I uptake correlated with the site of uptake on the initial preablation DxWBS in 11 of 12 patients (92%). Only one patient in the rhTSH-RRA group had new uptake in the anterior superior mediastinal lymph node that was not seen on the preablation DxWBS (Figure 6).

At the time of initial <sup>131</sup>I-RRA, small-volume <sup>131</sup>I-avid metastases were identified in the lungs in eight patients (four each in the rhTSH-RRA and THW-RRA groups). Preoperatively, none had structurally identifiable tumor in chest radiographs or high-resolution chest CT after <sup>131</sup>I-avid disease was detected during ablation. For the eight patients with lung metastases, the mean (±SD) <sup>131</sup>I activity was 136±40 mCi. Abnormal foci of <sup>131</sup>I lung uptake were identified on the RxWBS in one patient in each group (one of four each in the rhTSH-RRA and THW-RRA groups) and were seen in all eight patients on the RxWBS study. After this initial RRA, three of the four patients in the rhTSH group (75%) and one of four (25%) in the rhTSH group were rendered NED (P = 0.49)' by comparison 75% of the rhTSH group with locoregional disease were rendered NED, as compared with 63% of the THW group with locoregional disease (P = 0.41). (Figure 7)

**CONCLUSION**

The first <sup>131</sup>I administration following total thyroidectomy for differentiated thyroid cancer has both an ablative and an adjuvant (tumoricidal) function.

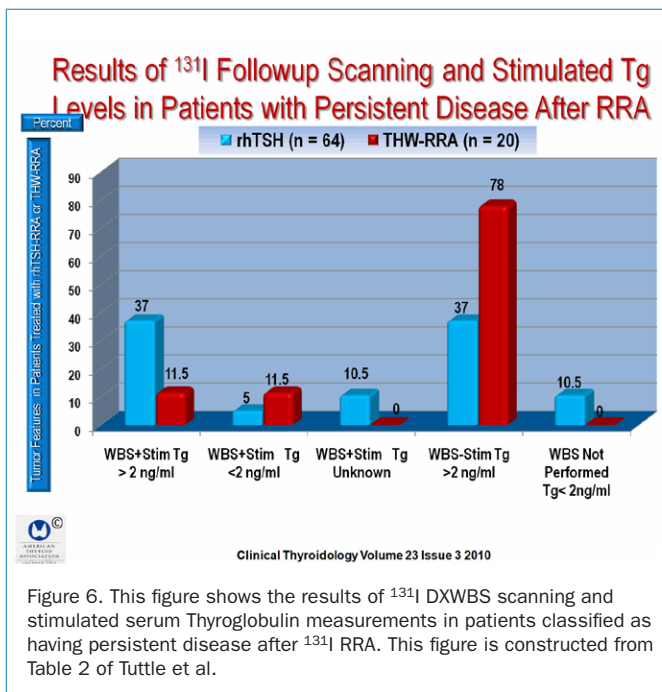


Figure 6. This figure shows the results of <sup>131</sup>I DXWBS scanning and stimulated serum Thyroglobulin measurements in patients classified as having persistent disease after <sup>131</sup>I RRA. This figure is constructed from Table 2 of Tuttle et al.

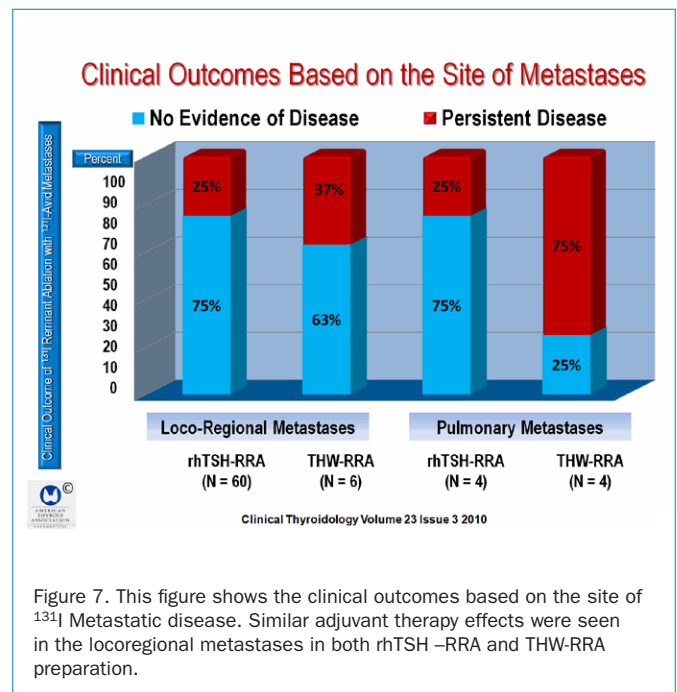


Figure 7. This figure shows the clinical outcomes based on the site of <sup>131</sup>I Metastatic disease. Similar adjuvant therapy effects were seen in the locoregional metastases in both rhTSH –RRA and THW-RRA preparation.

**COMMENTARY**

The aim of this study was to determine whether  $^{131}\text{I}$  effectively destroys previously undetected metastases in the process of performing RRA, either by rhTSH stimulation or THW. Although this seems to be a simple, straightforward goal, several variables have an impact on the final conclusion of this study. For instance, the first signal of residual disease in the 84 patients in this study was the finding of  $^{131}\text{I}$ -avid uptake outside the thyroid bed during the initial RRA. Metastases were found in 64 of the 84 patients (76%) who had rhTSH-RRA and 20 (24%) who had THW-RRA. This depends on the accuracy of RxWBS and the specific imaging studies used to identify the disease. Also, how the absence of disease is determined rests heavily on the outcome of the study. The results of this study show that rhTSH-RRA was successful as adjuvant therapy in 70% of the patients when NED was designated as a Tg  $<2$  ng/ml; however, when NED was designated as undetectable Tg, 30 of 84 patients (36%) were free of disease. The authors mention that in trying to determine whether the administered activity for RRA destroyed a specific tumor, they chose to use an outcome of either NED or persistent disease.

In a relatively recent prospective randomized study, Pilli et al. (1) performed a multicenter study of 72 patients with differentiated thyroid cancer aimed at identifying whether patients randomly assigned to receive 50 or 100 mCi for RRA by rhTSH preparation had similar outcomes. The outcome of rhTSH-RRA was assessed 6 to 8 months after the initial therapy. Successful RRA was designated as no visible uptake on a rhTSH-stimulated DxWBS, and an undetectable rhTSH-stimulated serum Tg  $<1$  ng/ml in 79% of the patients treated with 50 mCi and 67% in the group treated with 100 mCi ( $P = 0.46$ ), showing that therapeutic activities of 50 and 100 mCi of  $^{131}\text{I}$  were comparable, even in the presence of lymph-node metastases. In this group, lymph nodes were present at surgery in 13 patients, and 5 had lymph node metastases discovered on the rhTSH-RRA posttreatment scans. Thus, 18 patients had N1 at initial treatment and rhTSH-

RRA, 4 of whom had no evidence of disease after surgery, and in 11 patients lymph-node metastases disappeared after rhTSH-RRA and 2 patients had persistent disease. Of the patients with lymph-node metastases, most had uptake on the RxWBS. In most of these cases, rhTSH-RRA ablated not only the thyroid remnant but also the lymph-node metastases. The authors of this study mention that their study lacks long-term follow-up, and as a result, it cannot be interpreted as a definitive cure, but only as an indication of apparent remission. It remains uncertain whether smaller amounts of  $^{131}\text{I}$ , in the range of 50 mCi, can achieve a therapeutic effect on lymph-node metastases, although RRA can be successfully achieved with 30 to 50 mCi of  $^{131}\text{I}$  (2-4).

The study by Tuttle et al. also provides evidence that remnant ablation may destroy preoperatively unrecognized lymph-node metastases. The strength of this study is the large number of patients and the followup of nearly 3 years. One of the weaknesses of the study is the criteria used to identify patients with no evidence of disease. Patients were classified as having no evidence of disease if they had a negative DxWBS or a serum thyroglobulin (Tg)  $<2$  ng/ml, whereas patients were classified as having persistent disease if the DxWBS showed  $^{131}\text{I}$ -avid disease with or without a stimulated serum Tg  $>2$  ng/ml. The best criteria to identify tumor is a rising serum Tg level, or an undetectable serum Tg that fails to increase in response to TSH stimulation, either by THW or rhTSH, with no imaging evidence of tumor. In this regard, the Tuttle study falls somewhat short. The authors also mention that, their patients were treated and evaluated before they incorporated the routine use of single photon emission computed tomography (SPECT) imaging, and therefore, correlating  $^{131}\text{I}$  uptake with a specific structural abnormality could not be rigorously pursued. As a result, if the RAI-avid site was seen on the DXWBS prior to ablation, it is not possible to conclude with a  $^{131}\text{I}$  DXWBS study that the RAI-avid tumors were destroyed.

**Ernest L. Mazzaferri, MD, MACP**

**References**

1. Pilli T, Brianzoni E, Capocchetti F et al. A comparison of 1850 MBq (50 mCi) and 3700 MBq (100 mCi)  $^{131}\text{I}$ -iodine administered doses for recombinant TSH-stimulated postoperative thyroid remnant ablation in differentiated thyroid cancer. *J Clin Endocrinol Metab* 2007;92:3542-6.
2. Bal CS, Kumar A, Pant GS. Radioiodine dose for remnant ablation in differentiated thyroid carcinoma: a randomized clinical trial in 509 patients. *J Clin Endocrinol Metab* 2004;89:1666-73.
3. Maenpaa HO, Heikkonen J, Vaalavirta L et al. Low vs. high radioiodine activity to ablate the thyroid after thyroidectomy for cancer: a randomized study. *PLoS ONE* 2008;3:e1885.
4. Barbaro D, Boni G, Meucci G et al. Radioiodine treatment with 30 mCi after recombinant human thyrotropin stimulation in thyroid cancer: effectiveness for postsurgical remnants ablation and possible role of iodine content in L-thyroxine in the outcome of ablation. *J Clin Endocrinol Metab* 2003;88:4110-5.