

Preparation with recombinant human TSH or thyroid hormone withdrawal has similar therapeutic (tumoricidal) effects on small-volume metastases discovered incidentally during remnant ablation

Tuttle RM, Lopez N, Leboeuf R, Minkowitz SM, Grewal R, Brokhin M, Omry G, Larson S. Radioactive iodine administered for thyroid remnant ablation following recombinant human thyroid stimulating hormone preparation also has an important adjuvant therapy function. *Thyroid* 2010;20:257-63.

SUMMARY

BACKGROUND

Recombinant human thyrotropin (rhTSH) has been approved by the Food and Drug Administration (FDA) since 2007 for preparing patients for radioiodine (¹³¹I) remnant ablation (RRA) after total thyroidectomy in well-differentiated thyroid cancer without evidence of metastatic disease. Still, initially undetected metastases are often not found until ¹³¹I remnant ablation and a posttherapy whole-body scan are performed. The aim of this retrospective study was to determine whether ¹³¹I-avid metastatic tumors are associated with a significant therapeutic (tumoricidal) ¹³¹I effect after preparation of patients with rhTSH stimulation.

METHODS

Study Subjects

The study subjects were identified from 394 patients with differentiated thyroid cancer who had RRA at the Memorial Sloan-Kettering Cancer Center from 1997 through 2005. From this group of 394 patients, a total of 84 (21%) patients who had ¹³¹I uptake in the thyroid bed and well-differentiated papillary or follicular thyroid cancer without known distant metastases at the time of RRA were included in the study. Excluded were patients with known or suspected distant metastases and with known residual gross tumor in the neck, and patients with interfering antithyroglobulin (Tg) antibodies (TgAb).

None of the 84 patients had palpable locoregional tumors at the time of RRA, and cross-sectional imaging studies were not routinely performed at the time of RRA in patients with ¹³¹I-avid disease in the neck. However, chest computed tomography (CT) scans were performed in all patients who had ¹³¹I-avid uptake in the lungs, which permitted structural correlations in patients with pulmonary uptake on the postablation RRA scans, but not confined to the neck.

RRA Preparation

All patients had near-total thyroidectomy prior to RRA and all were instructed to follow a low-iodine diet for at least 1 week prior to ablation.

RESULTS

Patient Characteristics (Figures 1 and 2)

The study identified 84 patients with ¹³¹I-avid metastatic tumors localized outside the thyroid bed either on the initial ¹³¹I diagnostic scan (DxWBS) (63 of 84, 75%) or only on the posttherapy ¹³¹I scan (RxWBS) (21 of 84, 25%) all of which were visualized on both the DxWBS and the RxWBS. Of the 84 patients, 64 (76%) were prepared for RRA with rhTSH stimulation (rhTSH-RRA) and 20 (24%) were prepared with thyroid hormone withdrawal (THW-RRA). Most of the patients (81%) had an rhTSH-positive DxWBS 12 to 18 months after RRA. Patient age, sex, cancer histology, clinical TNM (tumor–node–metastasis classification), and tumor stage was not

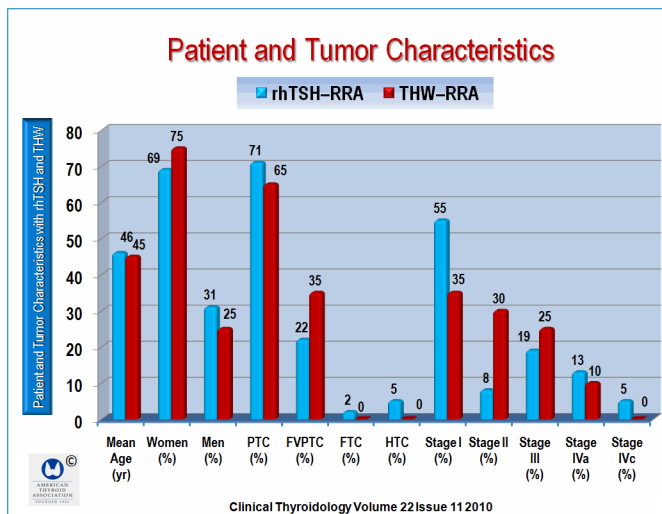


Figure 1. This figure shows the patient and tumor characteristics. FTC = follicular thyroid carcinoma; FVPTC = follicular variant papillary thyroid carcinoma; HTC = Hürthle cell carcinoma; PTC = papillary thyroid carcinoma; RRA = radioiodine remnant ablation; rhTSH = recombinant human thyrotropin; THW = thyroid hormone withdrawal. This figure and Figures 2 and 3 are derived from Table 1 of Tuttle et al.

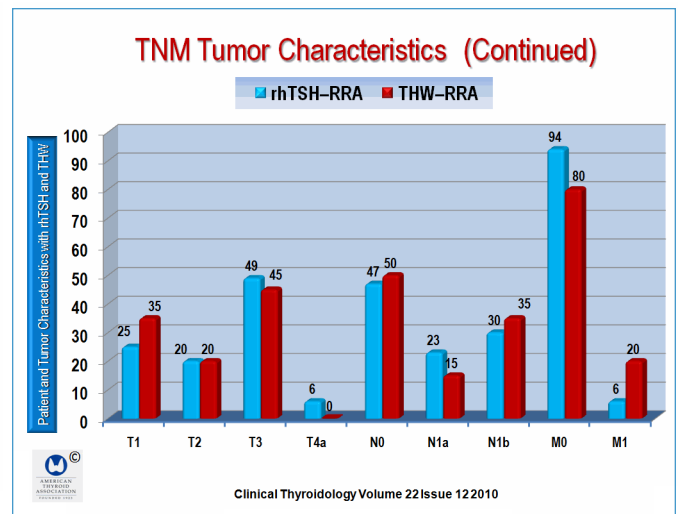


Figure 2. This is a continuation of Figure 1. The figure shows the TNM (tumor–node–metastasis staging system). RRA = remnant ablation; rhTSH = recombinant human thyrotropin; THW = thyroid hormone withdrawal. TNM = tumor–node–metastasis.

statistically different between the rhTSH and THW groups (Figures 1 and 2). All patients were initially thought to be M0 (no distant metastases) prior to RRA, but after the findings of ¹³¹I-avid distant metastases during RRA, the TNM diagnosis was upgraded in 8 patients to M1 (distant metastases present), of which 4 were in the rhTSH-RRA group and 4 in the THW-RRA group. The median administered ¹³¹I activity was 144 mCi in the rhTSH-RRA group and 108 mCi in the THW-RRA group (P = 0.307). The ¹³¹I-avid disease was initially detected on the DxWBS in most of the patients (75% of the rhTSH-RRA group vs. 90% in the THW-RRA group; P = 0.2).

Patients in both groups had RRA-avid tumor identified mainly as locoregional metastases alone (rhTSH-RRA, 60 of 64, 94%; THW-RRA, 16 of 20, 80%). The remaining patients had lung metastases alone or with both locoregional and lung metastases. The clinical outcomes were determined a median of 2.7 years after RRA.

Clinical Outcomes (Figure 3 and 4)

Although ¹³¹I-avid metastatic tumors were identified outside the thyroid bed at the time of initial ablation, 45 of 64 (70%) of the rhTSH-RRA group and 11 of 20 (55%) of the THW-RRA group were rendered NED (no evidence of disease) a median of 2.7 years after the initial ¹³¹I-RRA (P = 0.159) (Figure 2). Persistent disease was found in 19 of 64 patients (30%) following rhTSH-RRA and in 9 of 20 (45%) following THW-RRA (Figure 3). Cross-sectional imaging performed on all patients identified 5 of 19 (26%) in the rhTSH-RRA group and in 4 of 9 (44%) in the THW-RRA group with persistently abnormal Tg values during follow-up. Also, 1 patient in the rhTSH-RRA group also had non-¹³¹I-avid lung metastases and ¹³¹I-avid mediastinal lymph-node metastases (Figure 4).

An undetectable stimulated serum Tg <0.6 µg/L 12 to 18 months after RRA was achieved in 28 of 64 (44%) of the rhTSH-RRA group as compared with 6 of 20 (30%) of the THW-RRA group (P = 0.20). If the definition of NED was changed to an undetectable stimulated serum Tg value, 25 of 64 (39%)

of the rhTSH-RRA group and 5 of 20 (25%) of the THW-RRA group would be classified as NED 12 to 18 months after initial RRA (P = 0.19) (Figure 4).

¹³¹I-Avid Lesions Identified by DxWBS Prior to RRA (Figures 5 and 6, on next page)

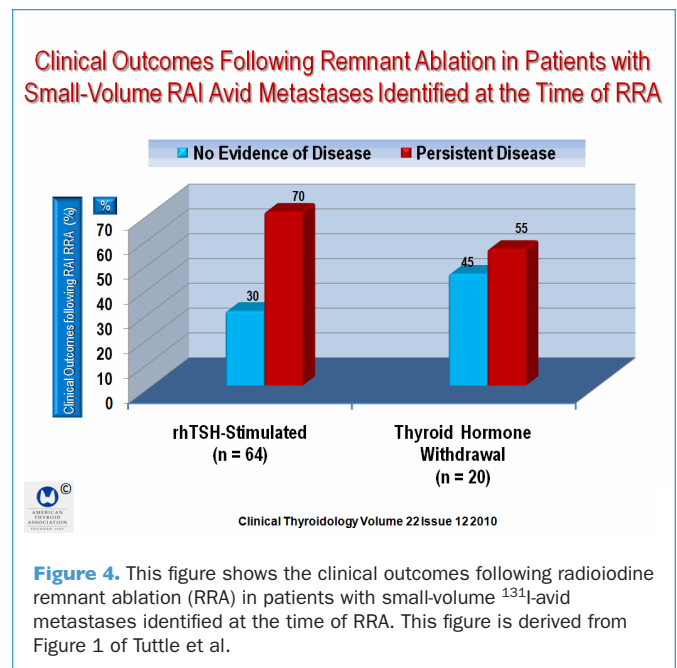
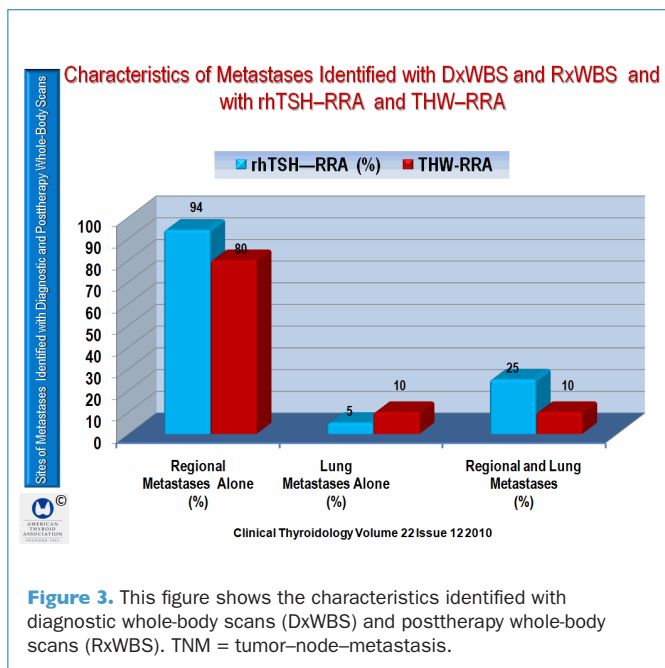
Concerning the outcome of ¹³¹I-avid lesions identified on the DxWBS studies prior to RRA, 48 in the rhTSH-RRA group and 18 in the THW-RRA group, follow-up rhTSH-stimulated DxWBS identified persistent tumor in the same locations in 9 of 48 (19%) of the rhTSH-RRA group and 0 of 18 of the THW-RRA group (P = 0.1). However, new sites of ¹³¹I-avid tumors were detected on the follow-up rhTSH-stimulated DxWBS in 1 of 48 (2%) of patients in the rhTSH-RRA group (with new uptake in the neck, and 1 patient with new uptake in the lungs), and 2 of 18 (11%) in the THW-RRA (1 patient with new uptake in the neck and 1 with new uptake in the lungs (P = 0.17) (Figure 6).

In the rhTSH-RRA group, identifiable tumor was associated with a stimulated Tg >2 µg/L in all five cases and a positive diagnostic DxWBS in one case. In the THW-RRA group, three of the four cases with structurally identifiable disease had a stimulated serum Tg >2 µg/L, and two of the cases had a positive DxWBS.

Among the patients classified as having persistent disease on the basis of a follow-up DxWBS, the site of persistent ¹³¹I uptake was correlated with the site of uptake on the initial preablation diagnostic scan in 11 of 12 patients (92%). One patient in the rhTSH-RRA group had new uptake in a mediastinal lymph-node metastasis, not seen on preablation ultrasonography.

CONCLUSION

Preparation with rhTSH or THW stimulation has a similar therapeutic (tumoricidal) effect on small-volume metastatic disease discovered incidentally at the time of remnant ablation.



Results of Radioactive Iodine Scanning and Stimulated Serum Tg Measurements in Patients with Persistent Tumor after RRA

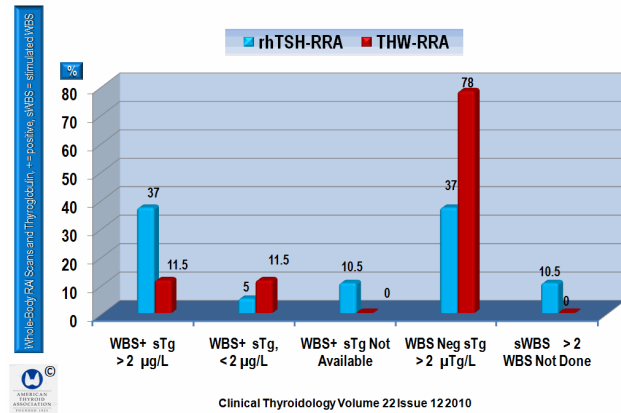


Figure 5. This figure shows the results of ¹³¹I scanning and stimulated serum Tg measurements in patients with persistent tumor after RRA. This figure is derived from Table 2 of Tuttle et al. RAI = radioactive iodine; RRA = radioiodine remnant ablation; rhTSH = recombinant human thyrotropin; sTg = stimulated serum Tg. sWBS = stimulated whole-body scan; THW = thyroid hormone withdrawal; WBS = whole-body scan.

Clinical Outcomes Following RRA in Patients with Small-Volume, RAI-Avid Metastases Identified at the Time of RRA

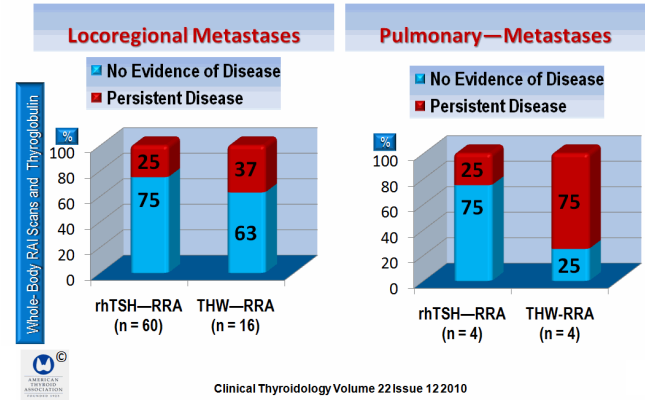


Figure 6. This figure shows the clinical outcomes based on the site of ¹³¹I metastatic disease. Similar adjuvant therapy effects were observed in locoregional metastases in both rhTSH-RRA and THW-RRA. RAI = radioactive iodine; RRA = radioiodine remnant ablation; rhTSH = recombinant human thyrotropin; sTg = stimulated serum Tg. sWBS = stimulated whole-body scan; THW = thyroid hormone withdrawal.

COMMENTARY

This study demonstrates the concept that the first treatment with ¹³¹I following total thyroidectomy for thyroid cancer has both an ablative and adjuvant therapy (tumoricidal) function. Tuttle et al. found that rhTSH-stimulated ¹³¹I ablation resulted in successful adjuvant therapy in 70% of the patients when ¹³¹I-avid metastatic tumors were first found at the time of remnant ablation, as compared with 55% of patients prepared with THW (P = 0.159).

Tuttle et al. point out that the data in this study are consistent with the earlier reports of successful adjuvant therapy of

incidentally discovered ¹³¹I-avid metastases with rhTSH preparation (1). However, Tuttle suggests that the relatively high rates of successful adjuvant therapy are probably largely related to the entry criteria in this study, and that only patients with small-volume ¹³¹I-avid metastases would have been included in this study, which might be expected (2).

This is an important study, but Tuttle et al. warn that this treatment may not be effective when macrometastases are present.

— Ernest L. Mazzaferri, MD, MACP

References

1. Pilli T, Brianzoni E, Capocchetti F, et al. A comparison of 1850 (50 mCi) and 3700 MBq (100 mCi) ¹³¹I-iodine administered doses for recombinant thyrotropin-stimulated postoperative thyroid remnant ablation in differentiated thyroid cancer. *J Clin Endocrinol Metab* 2007;92:3542-6.
2. Durante C, Haddy N, Baudin E, et al. Long-term outcome of 444 patients with distant metastases from papillary and follicular thyroid carcinoma: benefits and limits of radioiodine therapy. *J Clin Endocrinol Metab* 2006;91:2892-9.

CLINICAL THYROIDOLOGY FOR PATIENTS
 A publication of the American Thyroid Association

Clinical Thyroidology for Patients
www.thyroid.org/patients/ct/index.html