

Acute radiation thyroiditis that sometimes occurs with postthyroidectomy remnant ablation is directly related to thyroidal ¹³¹I uptake and not to the amount of ¹³¹I used for ablation

Cherk MH, Kalff V, Yap KS, Bailey M, Topliss D, Kelly MJ. Incidence of radiation thyroiditis and thyroid remnant ablation success rates following 1110 MBq (30 mCi) and 3700 MBq (100 mCi) post-surgical ¹³¹I ablation therapy for differentiated thyroid carcinoma. Clin Endocrinol (Oxf) 2008;69:957-62.

SUMMARY

BACKGROUND Radiation thyroiditis may be observed when a patient with thyroid cancer has a large postsurgical thyroid remnant that is treated with radioactive iodine (¹³¹I) or external-beam radiotherapy. When this occurs, possibly dangerous acute neck pain and swelling may develop. The aim of this study was to evaluate the relationships between thyroid remnant ¹³¹I uptake and radiation thyroiditis, and the rate of thyroiditis with 30 and 100 mCi of ¹³¹I (1110 and 3700 MBq [mCi x 37 = MBq]).

METHODS This was a retrospective study of patients who were treated postoperatively with either 30 mCi or 100 mCi of ¹³¹I to destroy the thyroid remnant. The amount of ¹³¹I was chosen according to the clinical features of the tumor and patient risk factors. Patients were classified as having insignificant thyroiditis if no treatment was required, mild thyroiditis if simple analgesics such as nonsteroidal antiinflammatory drugs (NSAIDs) were required, and severe thyroiditis if steroids were required. The criterion for successful thyroid remnant ablation was an absence of visible ¹³¹I uptake in the thyroid bed on a 2-mCi whole-body scan performed 6 to 12 months after ¹³¹I therapy.

RESULTS The study subjects comprised 183 patients (143 female [78%] and 40 male [22%]) ranging in age from 16 to 87 years; 139 (76%) had papillary thyroid cancer and 44 (24%) had follicular cancer. Sixty-eight patients (37%) were treated with 30 mCi of ¹³¹I and 115 (63%) were treated with 100 mCi.

Median ¹³¹I uptake by the thyroid remnant was 1 mCi (range, 0.4 to 2.1) in the entire group, 0.5 mCi (range, 0.25 to 1.4) in the 30-mCi group, and 1.4 mCi (range, 0.6 to 2.5) in the 100-mCi group. Median ¹³¹I uptake by the thyroid remnant was 1.8% (range, 0.85 to 4.6) in the 68 patients who received 30 mCi, and 1.4% (range, 0.6 to 2.5) in the group that received 100 mCi. Thyroiditis requiring treatment developed in 39 patients (21%), which was mild in 29 (16%) and severe, lasting 2 to 3 days, in 10 patients (5%). The incidence of thyroiditis was 12% in patients treated with 30 mCi and 27% in those treated with 100 mCi (P = 0.02) (Figure 1).

In patients who had follow-up, thyroid remnant ablation was incomplete in 8 of 35 (23%) with thyroiditis, and in 22 of 123 (18%) without thyroiditis (relative risk, 1.28; 95% confidence interval, 0.63 to 2.63; P = 0.51). The levels of thyroid remnant ¹³¹I uptake correlated with the incidence of thyroiditis (r = 0.51, P ≤ 0.0001), and for every 1-mCi increase in the remnant ¹³¹I uptake, the risk of thyroiditis increased by 64%. Severe thyroiditis did not occur with remnant ¹³¹I uptake < 2 mCi. Thyroiditis developed in 21 of 30 patients (70%) with remnant ¹³¹I uptake > 3 mCi; 9 cases (30%) were severe (Figure 2). There was no

significant difference in remnant ablation success rates for patients treated with 30 or 100 mCi (Figure 3). Among 58 of the 68 patients with follow-up who were treated with 30 mCi, the success rate of thyroid remnant ablation was 76%, as compared with an 84% success rate in the 100 of 115 patients with follow-up who were treated with 100 mCi (P = 0.30) (Figure 3).

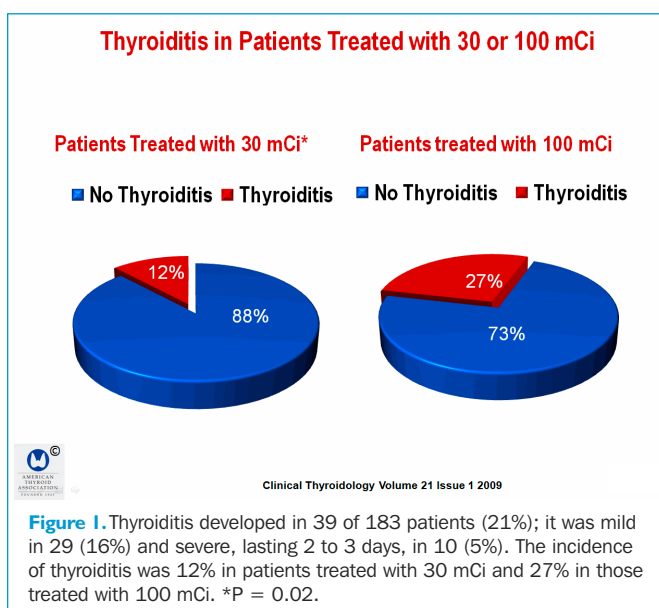


Figure 1. Thyroiditis developed in 39 of 183 patients (21%); it was mild in 29 (16%) and severe, lasting 2 to 3 days, in 10 (5%). The incidence of thyroiditis was 12% in patients treated with 30 mCi and 27% in those treated with 100 mCi. *P = 0.02.

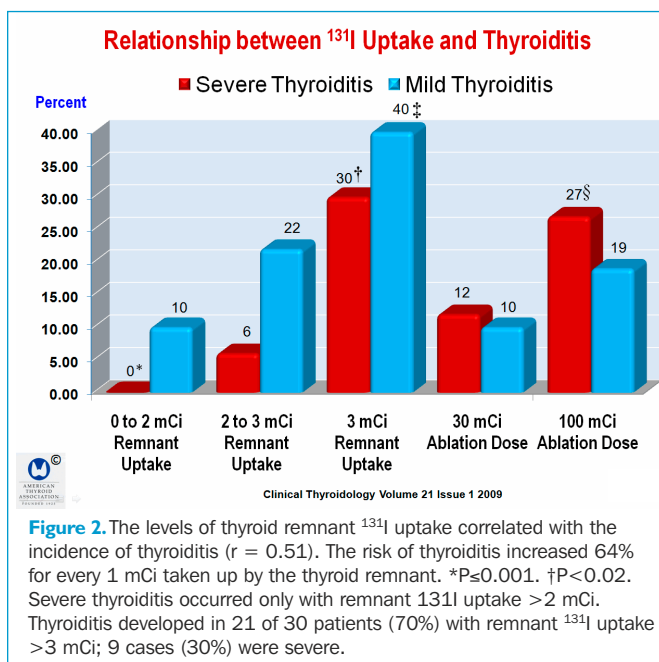
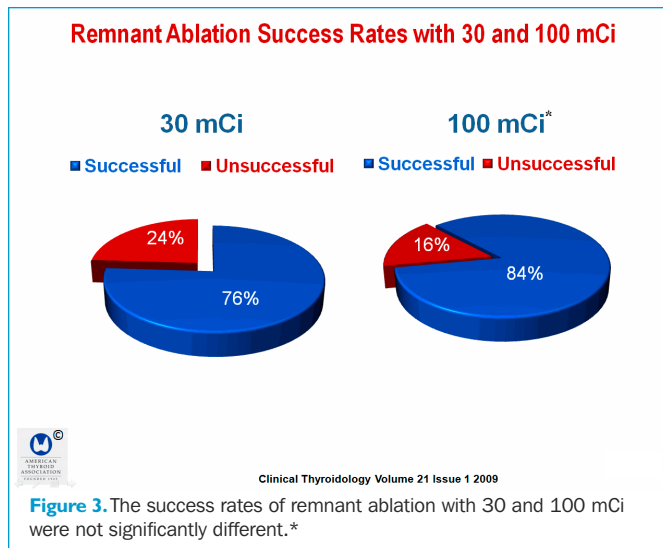


Figure 2. The levels of thyroid remnant ¹³¹I uptake correlated with the incidence of thyroiditis (r = 0.51). The risk of thyroiditis increased 64% for every 1 mCi taken up by the thyroid remnant. *P ≤ 0.001. †P < 0.02. Severe thyroiditis occurred only with remnant ¹³¹I uptake > 2 mCi. Thyroiditis developed in 21 of 30 patients (70%) with remnant ¹³¹I uptake > 3 mCi; 9 cases (30%) were severe.



CONCLUSION In patients with differentiated thyroid carcinoma, acute thyroiditis that sometimes occurs with postthyroidectomy remnant ablation is directly related to the amount of uptake of ¹³¹I by the thyroid and not the amount of ¹³¹I used for ablation.

COMMENTARY

Although acute thyroiditis that occurs when a large thyroid remnant is treated with ¹³¹I is well recognized by clinicians, little is written about the subject. Most of the time, radiation thyroiditis causes painful thyroid with the usual features of subacute thyroiditis. Still, symptoms vary from mild cases of pain and swelling to acute thyroid swelling requiring glucocorticoid therapy. There are few systematic studies of the incidence and clinical manifestations of radiation-induced thyroiditis caused by radionuclides or external-beam radiation. In one study, Burmeister et al. (1) found that radiation-induced thyroiditis occurred in 6 of 10 patients (60%) who were treated with 50 to 185 mCi of ¹³¹I after having undergone hemithyroidectomy or lobectomy. In contrast, there was only a 6% rate of thyroiditis in patients who had more extensive thyroidectomy—total or near-total thyroidectomy. The authors opined that the evidence supports a dose effect for the pathogenesis of these complications, and recommend <30 mCi of ¹³¹I for the initial thyroid remnant ablation in patients with substantial residual thyroid tissue remaining after surgery. The same caveat relates to external-beam radiation that inadvertently radiates the thyroid gland or is applied to the neck in patients with residual differentiated thyroid cancer in the thyroid bed. The symptoms of radiation thyroiditis vary, but generally comprise acute neck pain and swelling, with release of thyroid hormones from the gland, rarely causing acute thyrotoxicosis.

Nishiyama et al. (2) explored the incidence, effects and outcome of radiation-induced thyroiditis in a cohort of 22 patients undergoing external-beam radiation to the neck for nonthyroid problems, which incidentally exposed the thyroid gland to therapeutic doses of radiation. Measurements were made of serum thyrotropin (TSH), free triiodothyronine (FT₃) and total triiodothyronine (T₃), thyroxine (T₄), thyroglobulin, and antithyroid antibodies at

baseline and after approximately 40 Gy had been administered to the thyroid, after which the laboratory studies were repeated 3 and 6 months later. TSH underwent two phases of change. First, a significant change in serum TSH occurred right after radiotherapy, initiating a thyrotoxicosis phase, during which the TSH reached a nadir in 1 month, and later increased well above normal, in the range of 10 μIU/ml after 6 months during the hypothyroid phase. During the acute phase, T₃, FT₃, and T₄ increased only slightly and symptoms were minimal, but hypothyroidism later developed in some patients.

Bal et al. (3) performed ¹³¹I lobar ablation as an alternative to completion thyroidectomy in patients with differentiated thyroid carcinoma, using 15 to 60 mCi of ¹³¹I, depending on the size of the lobe and other patient features. Six months later, patients were evaluated with a whole-body ¹³¹I scan, a 48-hr ¹³¹I neck uptake, and a serum thyroglobulin measurement after levothyroxine withdrawal. The thyroid lobe was completely ablated in 53 patients (57%) after one dose of ¹³¹I and the remaining patients had partial thyroid ablation, with the mean radioiodine neck uptake being reduced to 3.1±2.4%. The mean first dose of ¹³¹I was 31.8±11.7 mCi, and the estimated mean absorbed dose was 251.3±149.3 Gy (range, 120 to 790). Approximately 30% of the patients in whom the remnant thyroid lobe was ablated with a single dose of ¹³¹I received ≤200 Gy. Moreover, the cumulative ablation rate was 92.1% after two doses of ¹³¹I, and only 7 patients needed a third dose of ¹³¹I. In all, 15 patients (16.1%) reported throat discomfort and neck pain. All were treated with mild analgesics, except for three patients who needed additional oral prednisolone for 7 to 10 days to overcome neck edema. Bal et al. concluded that ¹³¹I ablation of an intact thyroid lobe is possible and that it can be achieved with much smaller doses of radioiodine than previously believed. However, a systematic survey of patient symptoms and signs was not performed.

The main conclusion of the study by Cherk et al. is that radiation thyroiditis is directly related to the amount of ¹³¹I uptake by the thyroid and not the amount of ¹³¹I used for ablation. While this seems to be somewhat counterintuitive and at odds with the findings by Burmeister et al., the size of the thyroid remnant is directly related to the amount of ¹³¹I radiation given to the residual thyroid, which in turn is affected by the amount of ¹³¹I that is administered. There are several shortcomings in the study by Cherk et al. First, there are no data on thyroid-function tests or descriptions of the symptoms experienced by patients in whom severe thyroiditis developed. Second, follow-up was incomplete in a relatively large number of patients. Third, the extent of surgery was quite variable in patients treated outside the authors' medical center. Lastly, given the incomplete follow-up, it is not possible to reach a meaningful conclusion about the efficacy of using 30 mCi of ¹³¹I for remnant ablation. However, there are several prospective, randomized studies that clearly show that 30 to 50 mCi is sufficient for thyroid remnant ablation in the vast majority of patients, usually in the range of 80 to 90%, whether patients are prepared by thyroid hormone withdrawal or recombinant human TSH (4-7). The advice provided by Burmeister et al. appears to remain relevant.

Ernest L. Mazzaferri, MD, MACP

References

1. Burmeister LA, du Cret RP, Mariash CN. Local reactions to radioiodine in the treatment of thyroid cancer. *Am J Med* 1991;90:217-22.
2. Nishiyama K, Kozuka T, Higashihara T, et al. Acute radiation thyroiditis. *Int J Radiat Oncol Biol Phys* 1996;36:1221-4.
3. Bal CS, Kumar A, Pant GS. Radioiodine lobar ablation as an alternative to completion thyroidectomy in patients with differentiated thyroid cancer. *Nucl Med Commun* 2003;24:203-8.
4. Bal CS, Kumar A, Pant GS. Radioiodine dose for remnant ablation in differentiated thyroid carcinoma: a randomized clinical trial in 509 patients. *J Clin Endocrinol Metab* 2004;89:1666-73.
5. Pilli T, Brianzoni E, Capocchetti F, et al. A comparison of 1850 (50 mCi) and 3700 MBq (100 mCi) ¹³¹I-iodine administered doses for recombinant thyrotropin-stimulated postoperative thyroid remnant ablation in differentiated thyroid cancer. *J Clin Endocrinol Metab* 2007;92:3542-6.
6. Mäenpää HO, Heikkonen J, Vaalavirta L, et al. Low vs. high radioiodine activity to ablate the thyroid after thyroidectomy for cancer: a randomized study. *PLoS ONE* 2008;3:e1885.
7. Barbaro D, Boni G, Meucci G, et al. Radioiodine treatment with 30 mCi after recombinant human thyrotropin stimulation in thyroid cancer: effectiveness for postsurgical remnants ablation and possible role of iodine content in L-thyroxine in the outcome of ablation. *J Clin Endocrinol Metab* 2003;88:4110-5.